


Management of a 37-Year-Old Man with Recurrent Knee Pain

Case Study and Commentary, *Brian J. Cole, MD, MBA, Robert W. Frederick, MD, Andrew S. Levy, MD, and Kenneth R. Zaslav, MD*

CASE STUDY

Initial Presentation

 A 37-year-old man presents to his family physician complaining of a 3-month history of worsening left knee pain, swelling, and disability. The patient had been a collegiate-level soccer player. He is interested in resuming aerobic activity and would like to play soccer with his children but has been unable to do so because of his symptoms.

History

The patient denies any recent trauma to his left knee but states that approximately 1 year ago he completed a prolonged course of physical therapy for symptoms of medial-sided knee pain with activity-related swelling. The symptoms persisted following therapy, and he underwent arthroscopic surgery. During the procedure, a small portion of his medial meniscus was removed, and a damaged area of the “other cartilage” of his knee was smoothed with a shaver. There were no postoperative complications, and he successfully completed a 6-week course of physical therapy.

For the initial 9 months following surgery, the patient had near-complete relief of his symptoms. However, he has noted a gradual increase in activity-related pain and swelling along the inner aspect of his left knee. He complains of an occasional catching sensation and feels as if his knee will “give way” but denies a feeling of giving way when changing directions or pivoting. The pain is not significant at rest but is bothersome when the patient sleeps lying on the affected knee. He denies exacerbation of his symptoms while sitting or ascending/descending stairs. He states that he has difficulty squatting and kneeling due to stiffness. Regular use of ibuprofen has had no effect on his symptoms.

The patient’s medical history is not significant, and he denies involvement of any other joints. He is married, has 2 young children, and works as an attorney. He denies the use of tobacco and drinks socially. He takes no medications other than the recent use of ibuprofen.

Physical Examination

The patient is a healthy-appearing man, with a height of 6' and

a weight of 190 lb. He has mild but symmetrical varus alignment bilaterally and walks with a slight limp on the left side. Palpation of the left knee demonstrates a small intra-articular effusion and mild quadriceps muscle atrophy; left thigh circumference measured 10 cm from the proximal pole of the patella is 1 cm less than the contralateral side. McMurray’s test is negative, but the patient does complain of discrete tenderness along the medial femoral condyle and joint line. Active and passive range of motion in both knees is symmetrical, measuring from 0 degrees of extension to 135 degrees of flexion.

Assessment of muscle flexibility about the hip and knee reveals no side-to-side differences. Testing for gross laxity of the cruciate and collateral ligaments, including Lachman’s test, pivot shift test, reverse pivot shift test, and posterior drawer test, is negative. Straight-leg raising sign is not present, and there are no neurovascular abnormalities. Examination of the right knee and other joints is otherwise unremarkable.

Radiologic Evaluation

A supine non-weight-bearing anteroposterior (AP) radiograph in extension and lateral radiograph in flexion performed in the physician’s office do not demonstrate evidence of degenerative arthritis, occult fractures, bony or soft tissue lesions, or irregularities along the margins of the femoral condyles. A report of a magnetic resonance imaging (MRI) evaluation performed prior to the patient’s surgery states that there were no abnormalities except for a small signal increase within the most posterior aspect of the medial meniscus.

Brian J. Cole, MD, MBA, Assistant Professor, Sports Medicine and Orthopedics, Medical Director, Rush Cartilage Restoration Center, Rush-Presbyterian-St. Luke’s Medical Center, Chicago, IL; Robert W. Frederick, MD, Assistant Professor, Department of Orthopedics, Emory University School of Medicine, Atlanta, GA; Andrew S. Levy, MD, Assistant Professor of Orthopedics, New Jersey Medical School, Newark, NJ, Director, Center for Advanced Sports Medicine, Knee, and Shoulder, Summit, NJ; and Kenneth R. Zaslav, MD, Assistant Clinical Professor of Orthopedic Surgery, Medical College of Virginia, Chief of Sports Medicine, Advanced Orthopedic Centers, Richmond, VA.

- What are the most likely causes of this patient's recurrent symptoms?

Differential Diagnosis

The patient has already undergone a partial arthroscopic medial meniscectomy, and a lesion in the articular cartilage has been treated with shaving. Knee pain that is made worse with activity and is accompanied by swelling without frank ligamentous instability is unlikely to be caused by a torn ligament, infection, tumor, or systemic inflammatory condition. This patient's symptoms are more likely to be related to cartilage injury, such as a new meniscus tear, a discrete area of articular cartilage damage, or the onset of degenerative arthritis not readily appreciated by plain radiographs.

Osteochondritis dissecans is a developmental condition that commonly affects men in the second decade and produces symptoms similar to this patient's, including giving way, effusions, and mechanical symptoms. However, adults with this condition usually have obvious radiologic findings not present on this patient's radiographs. MRI findings are usually diagnostic.

A plica (ie, embryologic remnant of tissue), most commonly located along the medial side of the knee, can become symptomatic and cause a popping sensation with knee motion. Occasionally, a band of scar tissue resembling a plica can form postoperatively and cause similar symptoms. Osteonecrosis, more commonly seen in 50- to 60-year-old women, is associated with the sudden onset of pain at rest, painful weight-bearing, and effusions. In rare cases, a tibial stress fracture associated with osteoporosis or significant increase in weight-bearing activity occurs and is detected through a careful history and physical examination. A bone scan or MRI can be particularly helpful in making this diagnosis when radiographs are nondiagnostic.

Abnormal bone scans are likely in the presence of symptomatic osteoarthritis, meniscal tears, osteonecrosis, and osteochondral lesions. Thus, clinical correlation is required for diagnosis. Alternatively, diffuse uptake may be associated with reflex sympathetic dystrophy.

- What are the 2 primary types of cartilage found in the knee?
- What is the pathophysiology of articular cartilage disease?
- How is focal cartilage injury differentiated from degenerative arthritis?

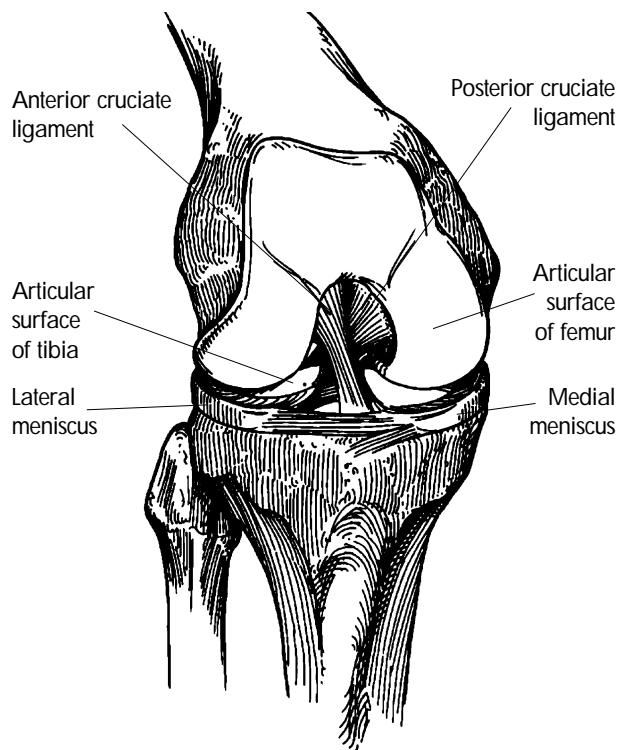


Figure 1. Anatomy of the knee demonstrating the bony surfaces with articular cartilage covering, medial and lateral menisci, and cruciate ligaments.

Knee Cartilage

There are 2 types of cartilage in the human knee joint: (1) fibrocartilage, of which the meniscus is comprised, and (2) articular, or hyaline, cartilage, which covers the surfaces of bone in the joint. Intact meniscal and articular cartilage are necessary for smooth and painless range of motion.

The Meniscus

The meniscus is a crescent-shaped pad of highly organized fibrocartilage that partially covers both the medial and lateral tibial plateaus (**Figure 1**). The main function of the meniscus is to distribute force over a greater surface area, thus acting as a shock absorber to protect the articular cartilage from damage. The meniscus also contributes to joint stability and lubrication. The matrix of the meniscus consists primarily of type I collagen and extracellular proteins.

Acute meniscal tears are generally caused by pivoting or twisting injuries and may produce joint-line pain, swelling, catching, and even locking with significant knee joint dysfunction. These tears often occur in association with other pathology such as an anterior cruciate ligament (ACL) tear. Degenerative meniscal tears may develop and become symptomatic over time, similar to the osteoarthritis that

develops in articular cartilage. Tears located in the outer third of the meniscus have a greater healing capacity due to the more abundant vascular supply to this area. Conversely, the inner meniscal rim is relatively devoid of vascular supply and heals less predictably. Unstable symptomatic meniscal tears unresponsive to conservative treatment respond well to arthroscopy and repair when they are peripherally located and relatively simple in configuration. Centrally located tears or those that are complex in configuration respond well to partial meniscectomy. Occasionally, when the entire meniscus is torn or fragmented, complete removal (total meniscectomy) is necessary. The interrelationship between the loss of the load-bearing role of the meniscus following meniscectomy and the development of arthritis is well documented, with loads increasing up to threefold in the involved compartment [1-3]. Because of the increased risk for developing secondary osteoarthritis following meniscectomy, every effort should be made to preserve and repair the meniscus when possible.

Articular Cartilage

Articular cartilage is found at the ends of long bones and covering the articular surface of sesamoid bones such as the patella (Figure 1). Its primary function is to provide a smooth, mobile, low-friction weight-bearing surface that protects the underlying subchondral bone. Injury to the articular cartilage may result in degenerative arthritis, leading to knee pain, swelling, and functional limitations [4,5].

Articular cartilage consists of a relatively sparse population of cells called chondrocytes (less than 10% of dry weight). Chondrocytes are responsible for the majority of articular cartilage's metabolic activity and are encased in the matrix, which they are responsible for synthesizing and maintaining. The extracellular matrix of articular cartilage consists primarily of collagen, proteoglycan aggregates (ie, aggrecan), and water. Together these components confer strength and durability as well as the smooth gliding properties that protect the underlying bone. Ninety percent of the collagen in articular cartilage is type II, which makes the cartilage resistant to shear and tension [6,7]. The proteoglycans present in articular cartilage bind water and account for the swelling pressure that makes it highly resilient to compressive loads.

Histologically, articular cartilage is organized into 4 distinct layers, with the calcified layer effectively linking the deep uncalcified cartilage to the underlying bone at the subchondral bone plate [6-8]. Injury or degeneration at the surface or deep layers can cause significant problems because of articular cartilage's negligible capacity for self-repair [9-17]. This poor healing response is due to the lack of blood supply to the chondrocytes and the inability of mature chondrocytes to migrate and replicate into an injured or degenerated area. Thus, superficial cartilage injuries that do not penetrate the vascular subchondral bone remain and may enlarge

for several years following the initial injury, potentially leading to diffuse degenerative arthritis [18]. Conversely, full-thickness cartilage defects that penetrate the vascular subchondral bone permit local access to an undifferentiated cell pool (primitive mesenchymal stem cells) capable of forming fibrocartilage, or scar cartilage. Fibrocartilage formation consists predominately of type I collagen and is the biologic basis for marrow-stimulating techniques used to treat symptomatic focal cartilage defects (see Surgical Treatment Options below).

Pathophysiology of Articular Cartilage Disease

Abnormal shear and blunt traumatic forces transmitted to the junction of the uncalcified and calcified cartilage layers can cause isolated cartilage injury known as focal cartilage defects. The depth of these defects ranges from partial-thickness to full-thickness extending down to the subchondral bone. This process is different from the mild superficial fissuring and scuffing (ie, chondromalacia) of articular cartilage, which most often is asymptomatic and does not require treatment.

Typically, focal articular cartilage lesions on the femur result from shear stress due to a twisting injury, and in the patellofemoral joint from direct trauma to the front of the knee [17,19-21]. The natural history of an asymptomatic focal cartilage defect and the defect's relationship to the development of secondary degenerative change typically seen in osteoarthritis is poorly understood. However, untreated lesions that remain symptomatic will inexorably progress, leading to degenerative changes characteristic of osteoarthritis and to the development of reciprocal changes on the opposing articular surface [6,22,23].

Primary osteoarthritis is a progressive wear-and-tear degenerative condition that increases in prevalence nonlinearly with age after 50 years. It is estimated that 25% to 30% of people 45 to 64 years of age and more than 85% of individuals older than 65 years have radiographically detectable osteoarthritis [24]. The incidence of secondary osteoarthritis resulting from focal articular damage is not well described, but it is believed to be exacerbated when associated with even partial meniscectomy [3].

Focal Cartilage Injury versus Degenerative Arthritis

Differentiating the pathophysiology of cartilage lesions from that of osteoarthritis is often difficult, as both types of lesions have similar inherent biologic, mechanical, and macroscopic features. These similarities suggest that both conditions may be part of a continuum of joint deterioration. Theoretically, abnormal stress concentration at the bone-cartilage junction first leads to a focal cartilage defect. Through a process of local lesion expansion and biologic or mechanical cartilage failure, reciprocal "kissing" lesions on opposing joint surfaces ultimately may develop. With time, large areas of cartilage

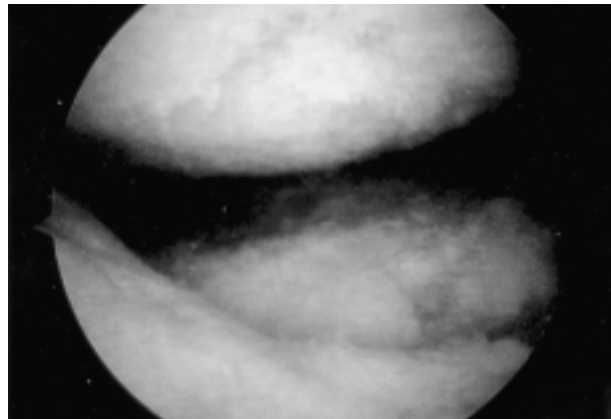
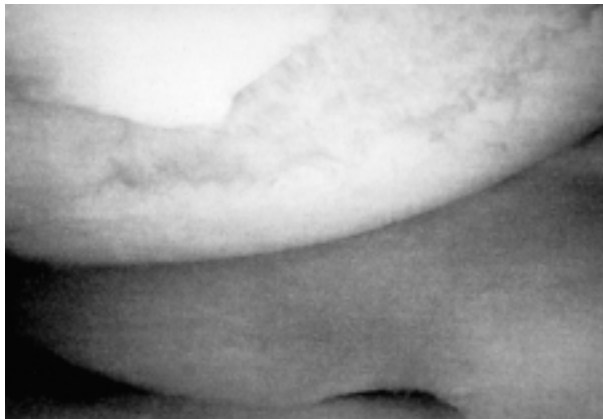


Figure 2. A focal cartilage defect (left) and degenerative arthritis (right) seen arthroscopically.

loss may lead to the radiographic findings typically associated with osteoarthritis, including joint-space narrowing, osteophytes (ie, bone spurs), loss of bony architecture, and subchondral sclerosis. Other factors such as genetic predisposition, wear due to mechanical debris, repetitive trauma, absent or torn menisci, limb malalignment, and ligamentous instability invariably contribute to the timing and severity of secondary osteoarthritis as an endpoint of disease progression once focal cartilage defects develop.

Arthroscopy performed by an orthopedic surgeon is often required to determine the source of a patient's symptoms and whether an articular cartilage defect is amenable to further surgical intervention. Seen arthroscopically, both isolated full-thickness cartilage defects and osteoarthritis may involve exposed subchondral bone. However, on macroscopic evaluation, a full-thickness or a symptomatic partial-thickness cartilage defect usually appears as an isolated divot in the articular cartilage, whereas osteoarthritis often appears as diffuse fraying, fibrillation, and thinning of the articular cartilage (**Figure 2**).

-
- **How common are focal cartilage defects?**
 - **What aspects of the history and physical examination are most useful for making the diagnosis of a focal cartilage defect?**
-

Prevalence of Focal Cartilage Defects

The isolated chondral injury was not well described in the literature until 1987 [25]. We now know that an estimated 900,000 Americans suffer articular cartilage injuries each year. In a recent attempt to delineate the prevalence of chondral lesions, Curl et al [26] reviewed 31,516 arthroscopies over a 4-year period. The authors noted 53,569 articular car-

tilage lesions in 19,827 patients. In patients younger than 40 years, full-thickness lesions of the femur were present in 5% of all arthroscopies.

Evaluation

A complete history and physical examination of the spine, neurovascular system, and contiguous joints are imperative to avoid missing additional potential sources of knee symptoms. If the clinical presentation is not consistent with findings on physical examination, then alternative diagnoses such as primary pathology of the hip or back with referred pain to the knee must be considered.

History

The history should focus on the patient's symptoms, including symptom location, type, and timing and response of symptoms to interventions. Regardless of the etiology, patients with a symptomatic focal cartilage defect classically present with complaints of relatively localized pain and activity-related swelling or stiffness. Mechanical symptoms such as catching or grinding due to articular surface irregularities and an occasional giving-way sensation may be elicited. Patients with osteoarthritis may complain of worsening symptoms during barometric pressure changes, whereas patients with osteonecrosis typically complain of pain at rest. Unfortunately, many patients with focal articular cartilage defects have vague and nonspecific complaints that are difficult to correlate with the severity of articular cartilage pathology. Thus, obtaining a history of earlier injuries, such as a direct trauma to the knee or prior surgical intervention with review of surgical findings, is instrumental in making the diagnosis. The clinician should be aware that chondral lesions might present after a single traumatic episode or following repetitive loading. The presence of knee pain with the following activities should be determined: sitting, standing, walking on level ground and inclines, ascending/descending stairs, turning in bed, squatting and kneeling,

Table 1. Components of a Comprehensive Musculoskeletal Physical Examination

Habitus
Alignment
Varus (bow-legged)
Valgus (knock-kneed)
Gait
Antalgic
Flexed-knee
Recurvatum (hyperextension)
Compensatory
Thrust
Varus (lateral)/Valgus (medial)
Swelling
Soft tissue
Effusion
Ligament laxity
Anteroposterior (ACL/PCL)
Medial-lateral (MCL/LCL)
Range of motion
Strength/muscle atrophy
Specific compartments
Tibiofemoral
Patellofemoral
Meniscus
Joint-line tenderness
Provocative maneuvers
Related joints
Spine
Hips
Feet
Neurovascular

ACL = anterior cruciate ligament; LCL = lateral collateral ligament; MCL = medial collateral ligament; PCL = posterior cruciate ligament.

carrying loads, and twisting or pivoting. Patient occupation, as well as past, present, and desired activity levels must be discussed in order to ascertain the patient's expectations.

Physical Examination

The components of a comprehensive physical examination are outlined in **Table 1**. Body habitus and gait should be observed. Antalgic postures or gaits may be present due to painful weight-bearing on the involved knee, or adaptive gait patterns such as in-toeing or out-toeing or a flexed-knee

gait may develop as the patient shifts weight away from the affected area. When present, static limb alignment and deformity are a rough index of the duration and severity of underlying osteoarthritis. Range-of-motion testing with side-to-side comparisons is usually normal in patients with isolated focal cartilage defects. Patients with long-standing degenerative arthritis may have flexion contractures and lack full flexion compared to normal. Favoring of a symptomatic knee and even small effusions are often associated with some degree of quadriceps atrophy. Patients may complain of swelling when in fact they perceive stiffness, as evidenced by a palpable effusion. Effusions are best appreciated by "milking" the joint fluid from the proximal to distal section and simultaneously balloting the patella. Palpating the bony prominences along the medial or lateral femoral condyles with the knee in 90 degrees of flexion will often cause pain in patients with symptomatic focal cartilage defects in these respective areas. A sense of crepitus, catching, or grinding through active and passive ranges of motion over the area in question can occur with focal irregularities in the cartilage surface.

Signs of soft tissue swelling and tendonitis should be evaluated. Pes anserinus bursitis is appreciated by direct palpation of the anteromedial tibial surface 2 finger-breadths beneath the medial joint line. Patellar tendonitis is best appreciated by displacing the patella distally with the leg in extension and directly palpating the patellar tendon. Prepatellar bursitis is associated with well-contained soft-tissue swelling anterior to the patella; the affected knee occasionally is warmer than the contralateral knee and may be erythematous or have cellulitis. Iliotibial band friction syndrome may cause discrete tenderness over the lateral epicondyle of the femur or at the insertion site of the iliotibial band that is exacerbated by repetitive flexion and extension of the knee during direct palpation of these areas. A peripatellar plica is most often located along the medial compartment and is best appreciated by a repetitive snapping sensation along the medial knee with range of motion as the plica catches over the medial femoral condyle. This sign can be confused with a medial meniscus tear.

Stability in the coronal plane (varus or valgus stress at 0 and 30 degrees of flexion) and sagittal/AP plane should be tested. To test for ACL stability, Lachman's test should be performed with the knee in 30 degrees of flexion with one hand stabilizing the distal femur and one hand translating the proximal tibia anteriorly to determine the amount of translation and whether there is a firm endpoint (**Figure 3**). Loss of the normal 5 to 10 mm of anteromedial tibial step-off relative to the medial femoral condyle with the knee in 90 degrees of flexion or a visible posterior sag of the tibia relative to the femur with the hip and knee in 90 degrees of flexion may indicate posterior cruciate ligament insufficiency.

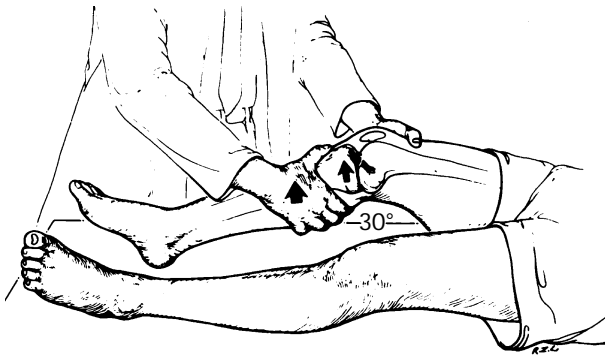


Figure 3. Lachman's test to assess for anterior cruciate ligament (ACL) insufficiency is performed with the knee in 30 degrees of flexion. (Reprinted with permission from Tria AJ, Klein KS. An illustrated guide to the knee. New York: Churchill Livingstone; 1992:50.)




Figure 4. McMurray's test to assess for meniscal pathology. Note flexion of the hip and knee, rotation of the tibia, and position of the fingers along the joint line. (Adapted with permission from Insall JN. Examination of the knee. In: Insall JN, editor. Surgery of the knee. New York: Churchill Livingstone; 1984:55-72.)

Meniscal pathology is determined by evaluating for joint-line tenderness and swelling and by provocative testing with McMurray's test. This test is performed by flexing the knee to approximately 90 degrees or more and applying medial or lateral stress (varus or valgus) simultaneously with compression and rotation to elicit discomfort and catching on the side of the involved meniscus (**Figure 4**). The hip, back, and neurovascular status are evaluated for additional pathology.

- What radiographs are useful for assessing knee pain in the office setting?
- What other imaging studies are useful?

Diagnostic Imaging

Reproducible radiographs are examined in a systematic manner. Careful comparison of affected and unaffected knees helps to document even subtle radiographic changes. A standard AP view with the patient standing in extension with his or her body weight evenly distributed on both legs is commonly obtained. A 45-degree flexion weight-bearing posteroanterior (PA) radiograph as described by Rosenberg and colleagues also is recommended (**Figure 5**) [27]. This view, which is similar to the traditional tunnel or notch view, will demonstrate subtle losses of joint space that traditional extension views may fail to show; such losses are indicative of early arthritis. Typically, the earliest loss of cartilage is in the 30- to 60-degree flexion zone and thus is easily overlooked with radiographs obtained in full extension. Symptoms of joint-line pain and a loss of cartilage clear space by 2 mm or more is likely to be due to chondrosis rather than meniscal pathology [27]. The 45-degree flexion

PA view allows for evaluation of changes consistent with chronic ACL deficiency, such as peaking of the tibial spines and narrowing of the intercondylar notch. The standard AP and 45-degree flexion PA views can be used to detect Fairbank's changes following meniscectomy, including osteophyte formation along the periphery of the tibia, flattening of the femoral condyles, and joint-space narrowing [28]. A non-weight-bearing lateral view with the knee in 45 degrees of flexion and an axial view of the patellofemoral joint complete the standard plain radiographic series.

Special studies such as a long-cassette mechanical axis view or an MRI evaluation should be ordered on an as-needed basis but are not part of the routine evaluation because of their cost and specific indications. Most often, the history, physical examination, and plain radiographs are all that is required to make the appropriate diagnosis. In most cases, if joint-space narrowing is present on the 45-degree flexion PA radiograph, MRI is not indicated.

MRI evaluation commonly underestimates the degree and extent of articular cartilage damage. However, if osteochondral fracture, osteonecrosis, or an isolated chondral defect is suspected, then an MRI may be informative. MRI is most useful in the setting of minimal arthritic change on

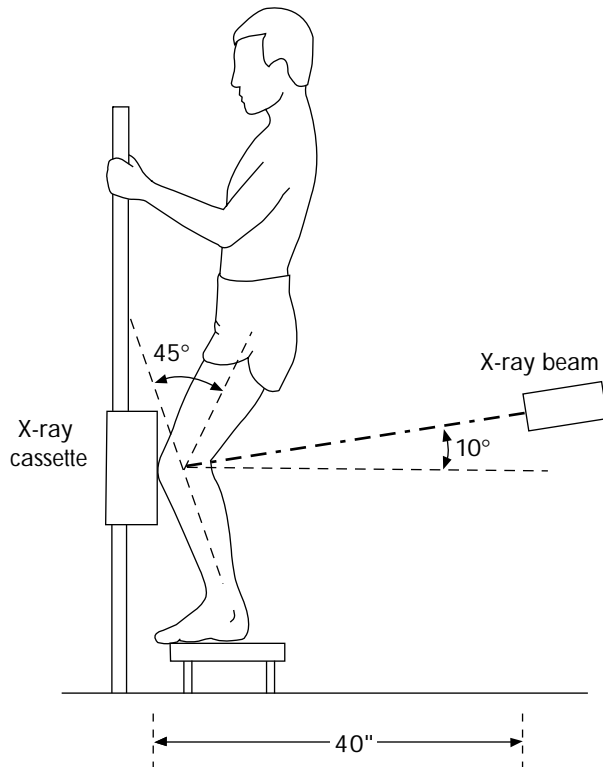


Figure 5. The 45-degree flexion weight-bearing posteroanterior (PA) radiograph. Note how the weight-bearing surfaces of the femoral condyles are brought into contact with the tibia to demonstrate even subtle joint-space narrowing. (Adapted with permission from Rosenberg TD, Paulos LE, Parker RD, Coward DB, Scott SM. The 45-degree posteroanterior flexion weight-bearing radiograph of the knee. *J Bone Joint Surg* 1988;70:1479.)

radiographs in patients with localized pain and clinical findings consistent with meniscal pathology. Degenerative meniscal tears commonly are present with osteoarthritis, and one should avoid operating solely on this finding without clinical correlation. Special MRI techniques to evaluate articular cartilage, including proton-density images, fat-suppression or saturation techniques, and gradient-echo techniques with or without intra-articular gadolinium, are gaining greater acceptance [29,30].

Diagnosis

Despite the absence of abnormalities on plain radiographs, the physician makes a provisional diagnosis of a symptomatic focal cartilage injury based on the information obtained from the physical examination, surgical history, and arthroscopic findings from the patient's previous surgery. The physician suggests a trial of exercise therapy that includes stretching, strengthening, and aerobic condi-

Table 2. Indications for Referral to an Orthopedic Surgeon

High-energy injury with direct trauma to the knee
Acute motion loss
Gross deformity
Acute neurovascular deficit
Mechanical symptoms
Catching
Locking
Sensation of a loose body
Failed nonsurgical management of more than 3 months' duration
Repeated giving way or complaints of instability

tioning. A follow-up appointment is scheduled for 6 weeks.

- **When is nonsurgical management of articular cartilage defects indicated?**
- **What nonsurgical therapeutic options are available?**

Nonsurgical Management

Because not all articular cartilage defects become symptomatic or lead to progressive arthritis, some defects may be observed until symptoms develop. Nonsurgical management for symptomatic lesions may be appropriate in relatively low-demand patients, in patients wishing to delay or avoid surgery, or in patients with degenerative osteoarthritis considered inappropriate for cartilage restoration. However, prolonged nonsurgical management of symptomatic cartilage lesions may lead to additional joint deterioration, making surgical intervention more difficult or less successful. Suggested indications for referral of patients to an orthopedic cartilage repair specialist (ie, an orthopedic surgeon with training and experience in cartilage restoration techniques) are shown in **Table 2**.

NSAID therapy with the lowest effective dosage is a nonsurgical option in patients without contraindications to these agents. Newer agents that are more selective inhibitors of the cyclooxygenase enzyme system offer a more favorable side-effect profile and are useful in patients with gastrointestinal disorders or on anticoagulation therapy [31]. Acetaminophen has become accepted as a first-line agent for pain relief when patients have minimal intra-articular swelling.

Chondroprotective oral supplements such as glucosamine and chondroitin sulfates are endogenous molecules in articular cartilage and have synergistic actions when taken together. Glucosamine is thought to stimulate chondrocyte and synoviocyte metabolism, and chondroitin sulfate is thought to inhibit degradative enzymes and prevent

fibrin thrombi formation in periarticular tissues [32–34]. The average cost of therapy is approximately \$50 per month depending on the agent used. Clinical studies demonstrate effective pain relief and increased function without toxicity or side effects [35]. Therapy should be discontinued if ineffective after 3 months.

Injections with corticosteroids or with a chondroprotective agent such as sodium hyaluronate are more appropriate for patients with low-grade osteoarthritis as determined by radiographic evaluation rather than for patients with an isolated articular cartilage defect. In general, these modalities are temporizing in nature and without long-lasting effects.

Activity modification with maintenance of ideal body weight and exercises emphasizing low-impact activities such as swimming or bicycling are recommended. Physical therapy has proven beneficial and may be prescribed as a home exercise program emphasizing range of motion, flexibility, and strengthening to help prevent minor translatory shifts at the knee and distribute weight-bearing more efficiently. Isometric quadriceps exercises are done with the patient in the supine position with the opposite knee and hip flexed and the foot resting on a flat surface; the leg to be exercised is in full extension. The quadriceps muscle is tightened and the leg is raised and lowered with 5-second pauses between directions. As repetitions become easier, ankle weights are added until a maximum of 8 to 10 lb for 20 repetitions can be performed twice a day. This program helps to improve quadriceps tension and minimize tibiofemoral and patellofemoral forces.

Isometric progressive-resistance hamstring exercises are performed in the prone position. With the thigh resting on the table, the patient flexes the knee to 20 degrees and begins isometric contraction of the hamstrings. As with quadriceps-strengthening exercises, the leg is held for 5 seconds between directions. A series of 20 repetitions should be performed twice each day, with weights added as tolerated.

Modalities such as ultrasound, iontophoresis, and electric stimulation are also helpful adjuncts when provided by a physical therapist.

Braces that unload the knee by applying a 3-point bending force at the level of the knee joint to redirect the location of the weight-bearing forces to healthier cartilage may be beneficial. However, these devices often are not tolerated well by patients due to their bulkiness and high cost. Horlick and Loomer [36] found significant improvement in osteoarthritic patients' pain and function using the Generation II Unloader brace (Generation II Unloader, Bothell, WA). Other series report similar results, but they evaluate patients with osteoarthritis rather with focal chondral defects [37,38]. Knee sleeves provide no biomechanical alterations in knee alignment or joint reaction force but may provide a sense of stability through enhanced proprioceptive feedback.

Therapy Failure



At the scheduled follow-up visit, the patient reports worsening symptoms. The physician refers him to an orthopedic surgeon with experience in cartilage restoration for further evaluation.

-
- What surgical treatment options are available for articular cartilage defects?
 - How is the most appropriate procedure selected for individual patients?
-

Surgical Treatment Options

The ultimate goals of any surgical option to treat articular cartilage defects in the knee are to restore the joint surface so that it provides a full range of motion without pain and to halt further degeneration of the cartilage. Many surgical options that have become available only within the past 5 years offer treatment alternatives for a relatively young and active population. This population is considered suboptimal for artificial joint replacement because of the activity limitations necessary to prevent early component failure. Long-term follow-up (10 to 20 years) is necessary to determine how successful cartilage repair techniques will ultimately be in achieving their goals. Currently, successful outcomes are measured by symptom reduction and improved function.

Conceptually, surgical treatment options for focal chondral defects can be described as palliative, reparative, restorative, and reconstructive. Palliative treatment includes arthroscopic debridement and lavage, which often provides short-term symptomatic relief. Reparative treatment includes marrow-stimulating techniques (MSTs), which create scar cartilage, or fibrocartilaginous repair tissue. Restorative techniques include autologous chondrocyte implantation (ACI) leading to the formation of hyaline-like cartilage, and osteochondral grafts (autografts or allografts) that transfer hyaline cartilage with its attached subchondral bone. Reconstructive procedures such as realignment procedures (osteotomy) and artificial joint replacement are often considered salvage options to be used when other options fail or are not specifically indicated in patients with extensive arthritis.

A number of factors must be considered when determining which surgical option is appropriate: the size of the defect (whether smaller or larger than 2 cm²); the number and types of previous surgeries (primary surgery or secondary surgery following failed primary surgery); location of the defect (femoral condyle, trochlea, patella, or tibial condyle); patient demands and expectations; and any coexisting pathology (ie, ligament tears, malalignment) (Table 3).

Table 3. Surgical Treatment Options for Symptomatic Focal Cartilage Defects of the Femur

Lesion	Treatment	Rehabilitation*	Comments
PRIMARY TREATMENT			
< 2 cm ²	Debridement and lavage	Straightforward	Provides short-term symptomatic relief
	Marrow-stimulation technique	Significant	Ideal for smaller lesions located on the femoral condyle; provides intermediate-term relief; low cost
	Osteochondral autograft	Moderate	Relatively new procedure; probably as good if not better than MST; provides potentially long-term relief
> 2 cm ²	Debridement and lavage	Straightforward	Provides short-term symptomatic relief
	Marrow-stimulation technique	Significant	Has lower success rate for larger lesions; good choice for symptomatic relief in low-demand individuals; intermediate-term relief is possible; low cost
	Cartilage biopsy for future autologous chondrocyte implantation	Straightforward	Staged procedure
	Osteochondral autograft	Significant	With larger lesions, potential for donor site morbidity exists; results are variable
	Osteochondral allograft	Significant	Useful for larger lesions with significant bone stock loss; small concern for disease transmission and allograft availability; provides potentially long-term relief
SECONDARY TREATMENT[†]			
< 2 cm ²	Osteochondral autograft	Moderate	Relatively new procedure; probably as good if not better than MST; provides potentially long-term relief
	Autologous chondrocyte implantation	Significant	High success rate for return to activities; potentially long-term relief; relatively high cost
> 2 cm ²	Osteochondral autograft	Significant	With larger lesions, potential for donor site morbidity exists; results are variable
	Osteochondral allograft	Significant	Useful for larger lesions with significant bone stock loss; small concern for disease transmission and allograft availability; provides potentially long-term relief
	Autologous chondrocyte implantation	Significant	High success rate for return to activities; potentially long-term relief; relatively high cost

NOTE: Procedure selection will ultimately depend on the patient's age, expectations, demand, and activity level, coexisting pathology, and extent and location of disease.

*Straightforward = early weight-bearing and return to activities within 4 weeks; moderate = short-term protected weight-bearing and return to activities within 12 weeks; significant = prolonged protected weight-bearing and significant delay until return to activities (6 to 8 months).

[†]Follows failed primary treatment.

Palliative Treatment

Debridement and lavage. Arthroscopic debridement and lavage removes the loose cartilage debris and inflammatory mediators believed to incite and maintain the pain and swelling associated with articular cartilage damage [39]. Mechanical debridement of loose and unstable cartilage may further reduce a patient's symptoms [40]. Most investigations have focused on patients with degenerative arthritis; in some cases, clinical results have lasted up to 5 years [41]. In relatively young or active patients with lesions larger than 2 cm², the clinical results achieved with debridement and lavage gener-

ally provide only short-term symptomatic relief [40,41]. Postoperative rehabilitation involves weight-bearing as tolerated and early strengthening exercises. Complications are rare and include persistent pain, stiffness, and infection [42].

Reparative Treatment

Marrow-stimulating techniques. MSTs transform partial-thickness cartilage injuries not extending to the underlying bone into full-thickness cartilage injuries, thus promoting some degree of repair through marrow-derived primitive mesenchymal stem-cell migration and vascular ingrowth [4]. The

common goal of the various MST techniques (ie, abrasion arthroplasty, subchondral drilling, and microfracture) is to penetrate the vascularized subchondral bone within the cartilage defect to create a conduit and site for clot formation containing mesenchymal stem-cells capable of forming scar (fibrocartilaginous repair) tissue [4,5,7]. Postoperatively, partial weight-bearing for 6 to 8 weeks may be required; occasionally, continuous passive motion is used to enhance the extent and quality of the repair tissue forming within the defect [8,43]. This procedure is ideal for lesions smaller than 2 cm² located on the femoral condyle. Authors have reported symptom relief in about two thirds of patients with lesions smaller than 2 cm² at 2 to 3 years follow-up [5,6,7]. Complications are generally similar to those associated with arthroscopy and debridement.

MSTs appear to have a lower success rate with trochlear lesions, tibial condyle lesions, and lesions larger than 2 cm² due to the relatively large loss of surrounding normal cartilage [5,6,7]. In low-demand individuals with defects greater than 2 cm², MSTs may be a good primary treatment option to provide symptomatic relief. Results, however, may deteriorate with time because fibrocartilage is less resilient compared with normal articular cartilage and has a tendency to break down, potentially leading to osteoarthritis. Because MSTs are a low-cost, relatively low-morbidity arthroscopic technique, they remain the mainstay for the initial management of small chondral lesions.

Restorative Treatment

Autologous chondrocyte implantation. ACI biologically resurfaces the joint that has sustained focal cartilage damage. The ACI technique uses the patient's healthy cartilage cells to repair the cartilage defect. These cells have been previously harvested arthroscopically from a minor load-bearing area of the knee joint and transformed into biologically active cells using a cell-culturing process. At the time of reimplantation, a periosteal (ie, the soft tissue covering bone) patch obtained from the upper tibia is sewn over the defect. The cartilage cells are injected beneath the patch, and the patch is sealed with fibrin glue. Postoperative rehabilitation involves protected weight-bearing and continuous passive motion.

Research indicates that this repair tissue looks and acts more like normal hyaline articular cartilage and may be biomechanically superior to the fibrocartilage formed in MSTs [44,45]. Studies performed in Sweden and the United States demonstrate durable and successful results in more than 80% of patients treated with this technique at minimum follow-up of 2 years [44]. The largest series by Peterson reported on 219 consecutive patients with an average 4-year follow-up (range, 2 to 10 years) and demonstrated good to excellent clinical results durable in more than 90% of lesions of the femoral condyle [46]. ACI remains a costly technique with a relatively lengthy recovery period and is most often used as a secondary

procedure for the treatment of smaller symptomatic focal cartilage defects (< 2 cm²). The procedure has a more than 90% success rate for return to sports and activities of daily living. ACI is also considered a primary treatment or secondary treatment option for larger lesions. Complications are rare but include arthrofibrosis, graft detachment, and infection.

Osteochondral grafts. Osteochondral autografts and cadaveric allografts are now being used more widely. Implantation of osteochondral plugs, or "mosaicplasty," involves taking small dowels of bone with their cartilage coverings from a minor non-weight-bearing portion of the femur and press-fitting them into the recipient hole created by the removal of the damaged cartilage. Protected weight-bearing and immediate range of motion is allowed postoperatively. This relatively new procedure, analogous to a hair-plug transplant, is most commonly indicated for the primary treatment of symptomatic focal cartilage defects on the femur smaller than 2 cm² and for similarly sized lesions for which a MST or ACI procedure has failed. Although long-term follow-up is lacking, results at 5 years suggest this treatment is at least as good if not better than MSTs [19,47,48]. Limitations include graft availability and thickness and contour mismatch. Complications are usually a result of technical difficulties of proper graft placement.

Large areas of bone and cartilage loss (> 2 cm²) can be managed with fresh or fresh-frozen, size-matched osteochondral allografts. Authors report good and excellent results for the treatment of femoral condyle lesions in 75% to 86% of patients at up to 10 years follow-up [16,17,19,20]. This is an excellent secondary treatment option for failed ACI in defects larger than 2 cm². However, the risk of disease transmission and logistic concerns regarding the procurement of fresh unirradiated osteochondral allografts limits the application of this technique.

Reconstructive Treatment


Realignment procedures. Patients with significant angular deformities of the knee such as genu varus or genu valgum often have relatively focal degenerative lesions of the articular surface on the side of the deformity. This condition can be treated with an unloading osteotomy, a procedure wherein a wedge of bone is removed from the tibia or femur in an effort to transfer the weight-bearing stress away from the damaged cartilage to the more healthy cartilage on the alternate side of the knee. Most authors report on the results following osteotomy of the knee in patients with degenerative arthritis rather than on patients with discrete focal cartilage damage. Nevertheless, results tend to be good or excellent in at least two thirds of these patients at a minimum of 5 years follow-up; conversion rates to total knee replacement at 10 years are relatively high [12-15]. Significant malalignment must be corrected independent of the degree of cartilage damage.

Joint replacement. Artificial joint replacement may be indicated as a tertiary treatment option for failed allograft transplantation or for end-stage osteoarthritis. Artificial joint replacement provides predictable symptomatic relief lasting about 10 to 15 years in patients older than 55 to 60 years of age before revision surgery may be required. In general, failure rates tend to be inversely proportional to age and activity level. Revision surgery for a failed joint replacement is technically demanding, is associated with compromised bone stock, and has higher complication rates.

Specific Defects

MSTs or ACI may be used to treat difficult cartilage lesions such as patella defects, but extensor mechanism malalignment must be corrected concurrently. Limited experience and outcomes data exist for the treatment of lesions of the patella and tibial condyle with ACI, osteochondral grafts, and MSTs.

Orthopedic Evaluation and Treatment

 After a thorough evaluation, the orthopedic specialist concludes that arthroscopy is indicated for the patient. During arthroscopy, a full-thickness focal cartilage lesion is noted on the medial femoral condyle; the lesion measures 6 cm² after gentle debridement of its edges. A cartilage biopsy is harvested for possible subsequent ACI. After arthroscopy, the physician and patient discuss treatment options. The physician explains that cartilage restoration options are indicated, given that the patient failed to achieve initial symptomatic relief from his first arthroscopic procedure and the lesion has since enlarged. His options include ACI and osteochondral grafting. Because of the lesion's relatively large size and focal nature and because of concerns for donor site morbidity (autograft) and the remote potential for disease transmission and limited graft availability (allograft), ACI is selected. The patient and physician discuss current literature supporting durable clinical results at an average of 4 years. Four weeks later, the patient undergoes second-stage implantation of his own cartilage cells.

Postoperatively, a continuous passive motion machine is used while the patient is in bed, and he wears a knee immobilizer when standing. Initially, he uses crutches to avoid weight-bearing and progresses to 20% weight-bearing over the next 6 weeks. Strengthening exercises are begun postoperatively and include isometric and quadriceps setting exercises. Full weight-bearing is permitted 6 weeks after the patient demonstrates the ability to straight-leg raise without an extension lag. At 14 weeks, he begins cycling and swimming. At 8 months, he resumes normal athletic activities.

Epilogue

The patient returns to his primary care physician for routine follow-up 1 year later. He reports that he is running and

playing recreational sports, including Sunday afternoon soccer with his children. He no longer experiences activity-related swelling and pain and feels that his knee function is nearly normal.

References

1. Dandy DJ, Jackson RW. The diagnosis of problems after meniscectomy. *J Bone Joint Surg [Br]* 1975;57:349-52.
2. Johnson R, Kettelkamp D, Clark W, Leaverton P. Factors affecting late results after meniscectomy. *J Bone Joint Surg [Am]* 1974;56:719-29.
3. Maletius W, Massner K. The effect of partial meniscectomy on the long-term prognosis of knees with localized, severe chondral damage. A twelve- to fifteen-year follow-up. *Am J Sports Med* 1996;24:258-62.
4. Furukawa T, Eyre DR, Koide S, Glimcher MJ. Biochemical studies on repair cartilage resurfacing experimental defects in the rabbit knee. *J Bone Joint Surg [Am]* 1980;62:79-89.
5. Steadman J, Rodkey W, Singleton S, Briggs K. Microfracture technique for full-thickness chondral defects: technique and clinical results. *Op Tech Ortho* 1997;7:300-4.
6. Johnson LO. Arthroscopic abrasion arthroplasty. Historical and pathological perspective: present status. *Arthroscopy* 1986;2:54.
7. Tippet J. Articular cartilage drilling and osteotomy in osteoarthritis of the knee. In: McGinty JB, Caspari RB, Jackson RW, Poehling GG, editors. *Operative arthroscopy*. New York: Raven Press; 1991:325-39.
8. O'Driscoll SW, Keeley FW, Salter RB. Durability of regenerated articular cartilage produced by free autogenous periosteal grafts in major full-thickness defects in joint surfaces under the influence of continuous passive motion. A follow-up report at one year. *J Bone Joint Surg [Am]* 1988;70:595-606.
9. Garrett JC. Osteochondritis dissecans. *Clin Sports Med* 1991;10:569-93.
10. Gross AE, Silverstein EA, Falk J, Falk R, Langer F. The allotransplantation of partial joints in the treatment of osteoarthritis of the knee. *Clin Orthop* 1975;108:7-14.
11. Meyers MH, Akeson W, Convery FR. Resurfacing of the knee with fresh osteochondral allograft. *J Bone Joint Surg [Am]* 1989;71:704-13.
12. McDermott AG, Finkelstein JA, Farine I, Boynton EL, MacIntosh DL, Gross A. Distal femoral varus osteotomy for valgus deformity of the knee. *J Bone Joint Surg [Am]* 1988;70:110-6.
13. Insall JN, Joseph DM, Msika C. High tibial osteotomy for varus gonarthrosis. A long-term follow-up study. *J Bone Joint Surg [Am]* 1984;78:1040-8.
14. Finkelstein AJ, Gross AE, Davis A. Varus osteotomy of the distal part of the femur. A survivorship analysis. *J Bone Joint Surg [Am]* 1996;78:1348-52.
15. Healy WL, Anglen JO, Wasilewski SA, Krackow KA. Distal femoral varus osteotomy. *J Bone Joint Surg [Am]* 1988;70:102-9.
16. Zukor DJ, Oakeshott RD, Brooks PJ. Small fragment osteochondral allografts for posttraumatic defects of the knee. In: Ewing JW, editor. *Articular cartilage and knee joint function:*

- basic science and arthroscopy. New York: Raven Press; 1990:153-65.
17. Garret J. Osteochondral allografts for reconstruction of articular defects. In: McGinty JB, Caspari RB, Jackson RW, Poehling GG, editors. Operative arthroscopy. Philadelphia: Lippincott Raven; 1996:395-403.
 18. Mankin HJ. The response of articular cartilage to mechanical injury. *J Bone Joint Surg [Am]* 1982;64:460-6.
 19. Bobic V. Arthroscopic osteochondral autograft transplantation in anterior cruciate ligament reconstruction: a preliminary clinical study. *Knee Surg Traumatol Arthrosc* 1996;3:262-4.
 20. Convery FR, Meyers MH, Akeson WH. Fresh osteochondral allografting of the femoral condyle. *Clin Orthop* 1991;273:139-45.
 21. Matsusue Y, Yamamuro T, Hama H. Arthroscopic multiple osteochondral transplantation to the chondral defect in the knee associated with anterior cruciate disruption. *Arthroscopy* 1993;9:318-21.
 22. Gillogly SD, Voight M, Blackburn T. Treatment of articular cartilage defects of the knee with autologous chondrocyte implantation. *J Orthop Phys Ther* 1998;28:241-51.
 23. Dandy DJ. Arthroscopic debridement of the knee for osteoarthritis [editorial]. *J Bone Joint Surg [Br]* 1991;73:877-8.
 24. Chang RW, Falconer J, Stulberg SD, Arnold WJ, Manheim LM, Dyer AR. A randomized, controlled trial of arthroscopic surgery versus closed-needle joint lavage for patients with osteoarthritis of the knee. *Arthritis Rheum* 1993;36:289-96.
 25. Outerbridge HK, Outerbridge AR, Outerbridge RE. The use of a lateral patellar autologous graft for the repair of the large osteochondral defect in the knee. *J Bone Joint Surg [Am]* 1995;77:65-72.
 26. Curl WW, Krome J, Gordon ES, Rushing J, Smith BP, Poehling GG. Cartilage injuries: a review of 31,516 knee arthroscopies. *Arthroscopy* 1997;13:456-60.
 27. Rosenberg TD, Paulos LE, Parker RD, Coward DB, Scott SM. The forty-five degree posteroanterior flexion weight-bearing radiograph of the knee. *J Bone Joint Surg [Am]* 1988;70:1479-83.
 28. Fairbank T. Knee joint changes after meniscectomy. *J Bone Joint Surg [Br]* 1948;30:664-70.
 29. Heron CW, Calvert PT. Three-dimensional gradient-echo MR imaging of the knee: comparison with arthroscopy in 100 patients. *Radiology* 1992;183:839-44.
 30. Potter HG, Linklater LM, Allen AA, Hannafin JA, Haas SB. Magnetic resonance imaging of articular cartilage of the knee. An evaluation with use of fast-spin-echo imaging. *J Bone Joint Surg [Am]* 1998;80:1276-84.
 31. Dewitt DL, Meado EA, Smith WL. PGH synthetase isoenzyme selectivity: the potential for safer nonsteroidal anti-inflammatory drugs. *Am J Med* 1993;95:405-55.
 32. Gosh P. Second-line agents in osteoarthritis. In: Dixon JS, Furst DE, editors. Second line agents in the treatment of rheumatic diseases. New York: Marcel Dekker; 1992:363-427.
 33. Bucci L. Chondroprotective agents: glucosamine salts and chondroitin sulfates. *Townsend Letter for Doctors* 1994;1:52-4.
 34. Muller-Fassbender H, et al. Glucosamine sulfate compared to ibuprofen in osteoarthritis of the knee. *Osteoarthritis Cartilage* 1994;2:61-9.
 35. Bougeous P. Efficacy and tolerability of chondroitin sulfate 1200 mg/day vs. chondroitin sulfate 3 x 400 mg/day vs. placebo. 3rd International Congress of the Osteoarthritis Research Society. Osteoarthritis in focus: etiopathogenesis, assessment, and treatment. Singapore, 7-9 June 1997. Abstracts. *Osteoarthritis cartilage* 1997;5 Suppl A:26-80.
 36. Horlick S, Loomer R. Valgus knee bracing for the osteoarthritic knee. *Clin J Sports Med* 1993;3:251-5.
 37. Hewett TE, Noyes FR, Barber-Westin SD, Heckman TP. Decrease in knee joint pain and increase in function in patients with medial compartment arthrosis: a prospective analysis of valgus bracing. *Orthopedics* 1998;21:131-8.
 38. Pollo FE. Bracing and heel wedging for unicompartmental osteoarthritis of the knee. *Am J Knee Surg* 1998;121:47-50.
 39. Edelson R, Burks RT, Bloebaum RD. Short-term effects of knee washout for osteoarthritis. *Am J Sports Med* 1995;23:345-9.
 40. Minas T, Nehrer S. Current concepts in the treatment of articular cartilage defects. *Orthopedics* 1997;20:525-38.
 41. Hubbard MJ. Articular debridement versus washout for degeneration of medial femoral condyle. A five-year study. *J Bone Joint Surg [Br]* 1996;78:217-9.
 42. Small N. Complications in arthroscopy: the knee and other joints. Committee on Complications of the Arthroscopy Association of North America. *Arthroscopy* 1986;2:253-8.
 43. Rodgrigo J, Steadman J, Silliman J, Fulstone H. Improvement of full-thickness chondral defect healing in the human knee after debridement and microfracture using continuous passive motion. *Am J Knee Surg* 1994;70:595-606.
 44. Brittberg M, Lindahl A, Nilsson A, Ohlsson C, Isaksson O, Peterson L. Treatment of deep cartilage defects in the knee with autologous chondrocyte transplantation. *N Engl J Med* 1994;331:889-95.
 45. Grande DA, Pitman MI, Peterson L, Menche D, Klein M. The repair of experimentally produced defects in rabbit articular cartilage by autologous chondrocyte transplantation. *J Orthop Res* 1989;7:208-18.
 46. Peterson L. Articular cartilage repair, regeneration and transplantation symposium. 65th Annual Meeting of the American Academy of Orthopaedic Surgeons. New Orleans, LA, 1998.
 47. Hangody L, Kish G, Karpati Z, Szerb I, Udvarhelyi I. Arthroscopic autogenous osteochondral mosaicplasty for the treatment of femoral condylar articular defects. *Knee Surg Sports Traumatol Arthrosc* 1997;5:262-7.
 48. Hangody L, Kish G, Karpati Z, Udvarhelyi I, Szigeti I, Bely M. Mosaicplasty for the treatment of articular cartilage defects: application in clinical practice. *Orthopedics* 1998;21:751-6.

Copyright 1999 by Turner White Communications Inc., Wayne, PA. All rights reserved.