

Technical Note

Allograft Interference Screw Fixation in Meniscus Transplantation

Jack Farr, M.D., R. Michael Meneghini, M.D., and Brian J. Cole, M.D., M.B.A.

Abstract: Allograft meniscus transplantation is indicated to restore proper knee biomechanics and prevent subsequent articular degeneration in patients with a meniscus-deficient knee. A variety of techniques for fixation of meniscal transplants exist, with some techniques using soft-tissue fixation of the meniscal horns and others using bony fixation. The authors present a technique of meniscus transplantation using a tibial slot with allograft interference screw fixation. We have had excellent early results with this technique and believe that a cortical allograft interference screw reliably maintains the anatomic position of the meniscal attachments that are critical to the biomechanics and functional outcome of meniscus transplantation. **Key Words:** Meniscus—Transplantation—Allograft—Arthroscopy—Interference screw.

Fairbank first reported radiographic degeneration in the knee following total meniscectomy in 1948.¹ Additional studies have shown radiographic evidence of cartilage degeneration after both complete and partial meniscectomy,^{2,3} with degeneration occurring more commonly after lateral meniscectomy rather than medial. Fairbank suggested the meniscus may have an important biomechanical role in force transmission across the knee joint.¹ Numerous studies⁴⁻⁷ have confirmed this important role by demonstrating a substantial decrease in total contact area and a dramatic increase in peak contact pressures in the involved knee compartment after excision of the meniscus.

Attempting to restore proper knee biomechanics and prevent subsequent articular degeneration provides the rationale for allograft meniscal transplantation. Short-term results are supportive,⁸⁻¹² yet inconsistencies with respect to patient selection, concomitant surgical procedures, and standardization of postoperative evaluation have made interpretation of these results difficult. Long-term results have not yet been reported on the structural integrity of the allograft meniscus while maintaining improved patient function, but clinical outcomes to date confirm efficacy.^{13,14} Furthermore, whether the restoration of near normal knee biomechanics via meniscal transplantation will ultimately prevent the progression of articular degeneration has yet to be determined.

A variety of techniques for fixation of meniscal transplants using soft-tissue fixation of the meniscal horns^{10,15} as well as bony fixation^{13,16-19} have been described. Multiple biomechanical studies⁴⁻⁷ have found improved tibial surface contact mechanics in meniscal transplants with both horns attached by bony fixation over menisci secured with soft-tissue fixation alone. The techniques of bone fixation include those utilizing separate bone plugs anchored in tunnels^{13,16} or by securing a common bone bridge with both horns of the meniscus attached into a transtibial channel.¹⁷⁻¹⁹

From the Cartilage Restoration Center of Indiana, Orthopaedics Indianapolis, Indianapolis, Indiana (J.F.); and the Department of Orthopaedic Surgery, Rush University Medical Center, Chicago, Illinois (R.M.M., B.J.C.), U.S.A.

Address correspondence and reprint requests to Brian J. Cole, M.D., M.B.A., Department of Orthopaedic Surgery, Rush College of Medicine, Rush University Medical Center, 1725 West Harrison St, Suite 1063, Chicago, IL 60612, U.S.A. E-mail: bcole@rushortho.com

© 2004 by the Arthroscopy Association of North America
0749-8063/04/2003-3579\$30.00/0
doi:10.1016/j.arthro.2004.01.009

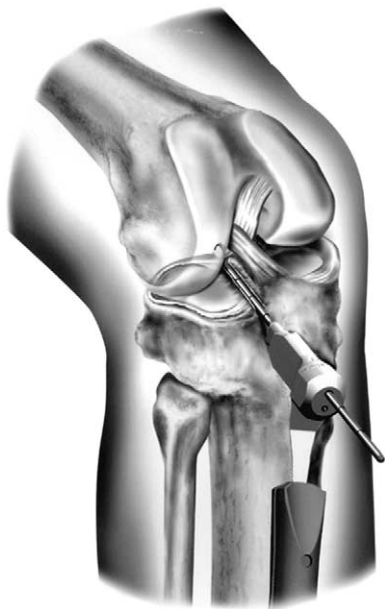

FIGURE 1. The guide positioned in the superficial tibial plateau reference slot.

Those techniques that employ common bone bridges in shaped channels, referred to as keyholes, troughs, and slots, use multiple methods of bony fixation. Interference screw fixation has excellent biomechanical properties^{20,21} and established clinical success²² in anterior cruciate ligament (ACL) reconstruction using the bone–patellar tendon–bone technique. We use an allograft cortical bone interference screw to obtain fixation of the bone bridge in meniscal transplantation. This method of fixation has shown excellent short-term results and maintains proper meniscal position radiographically without displacement of the allograft bone bridge.

TECHNIQUE

The patient is positioned in a well-padded leg holder and routine diagnostic arthroscopy is carried out through standard arthroscopic portals. Once the appropriate pathology is identified, the host meniscus is trimmed to create a stable meniscus–capsular bleeding rim for the transplant. A superficial reference slot is made on the tibial plateau in the anteroposterior (AP) direction. A pin is placed further inferior on the tibia using a guide positioned in the reference slot (Fig 1). A cannulated drill bit is used over the guide pin to create a blind tunnel (Fig 2) and a box cutter of the appropriate size is impacted to create a slot 7 or 8 mm

in width by 10 to 12 mm in depth (Fig 3). A rasp of the appropriate size is then used to smooth the slot to facilitate the allograft bone bridge insertion.

The allograft meniscus and bone bridge are then prepared. The allograft meniscus is sized according to preoperative plain film radiographs. This technique undersizes the bone bridge width by 1 mm, which allows adjustment of the bone bridge position in the AP direction while the meniscus is positioned to properly capture the femoral condyle. The bone bridge is sized to a width of 6 or 7 mm and a height 1 mm less than the tibial slot height. A vertical mattress suture is placed through the junction of the posterior and middle third of the meniscus (Fig 4). Using a single-barrel cannula, the suture is advanced through the capsule at the corresponding attachment site of the meniscus and exits through an accessory incision. The meniscus is passed through the arthrotomy into the knee with traction placed on the sutures to facilitate proper positioning of the meniscus.

As the meniscus is passed into the knee with the periphery of the host meniscus prepared (Fig 5), care is taken to align the bone bridge with the recipient tibial slot. The meniscus is properly positioned by cycling the knee through its range of motion and allowing the femoral condyle to engage and position the allograft meniscus. The slightly undersized meniscal bone bridge allows the meniscus to achieve its

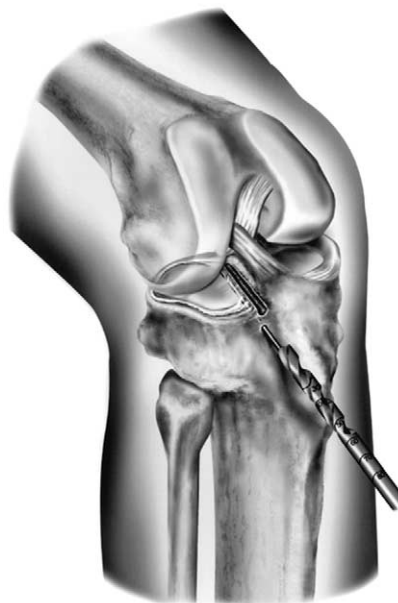

FIGURE 2. The cannulated drill bit used to create the tibial tunnel over the pin placed through the guide shown in Fig 1.

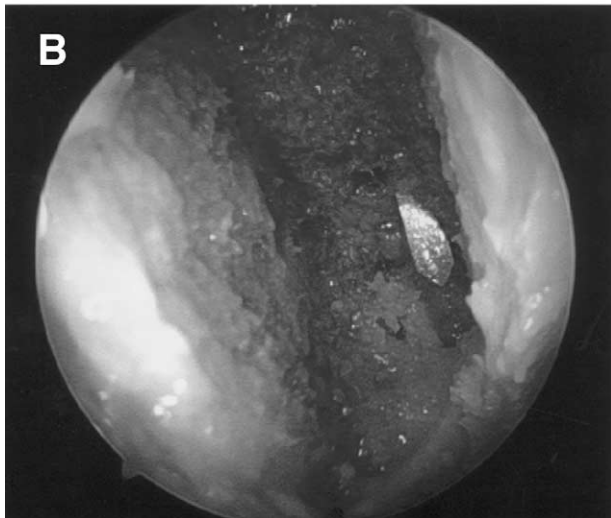
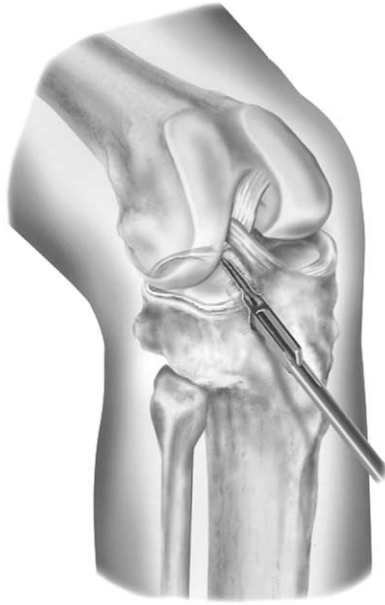A

FIGURE 3. (A) A box cutter is impacted over the guide pin into the tibial tunnel to create a slot 7 or 8 mm wide by 10 to 12 mm deep. (B) Arthroscopic intra-articular view of the tibial slot created by the box cutter.

proper position by sliding freely within the tibial slot in the AP direction. Once the proper AP bone bridge position is achieved, a guidewire is inserted between the bone bridge and the medial eminence side of the slot. A tap is inserted over the guidewire to create a path for the interference screw with the bone bridge held in place manually. An allograft cortical bone interference screw (Regeneration Technologies, Alachua, FL) is inserted adjacent to the meniscus on the side closest to the ACL tibial insertion site (Fig 6).

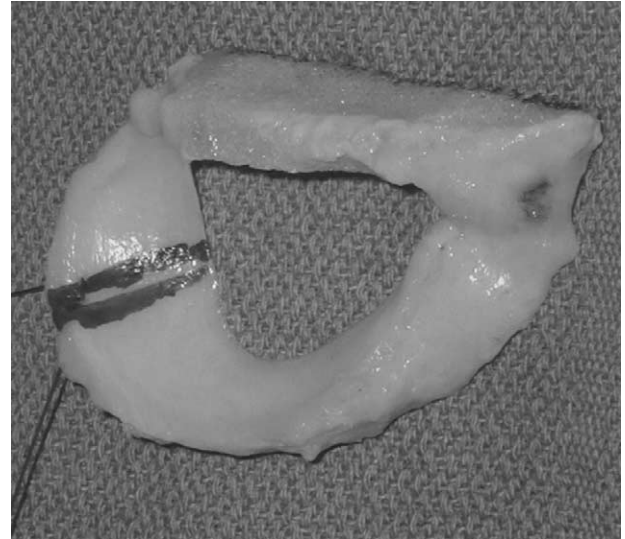

FIGURE 4. Vertical mattress suture placed through the junction of the posterior and middle third of the allograft meniscus.

Finally, vertical mattress sutures are used to complete the soft-tissue meniscal repair to the capsule using an inside-out technique (Fig 7).

Postoperative management includes progression from partial to full weight bearing over the first 4 weeks. A hinged knee immobilizer is used and range of motion while weight bearing is limited from 0° to 60° for the first two weeks and to 90° at 4 weeks to protect the meniscus repair. Non-weight bearing with

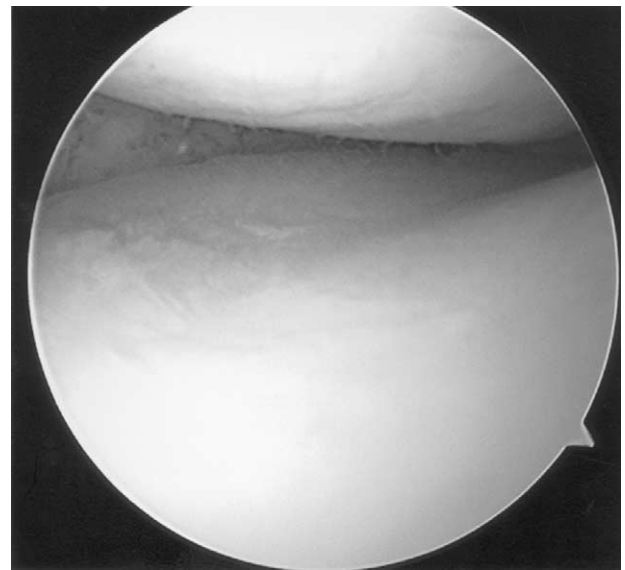


FIGURE 5. Arthroscopic view of the prepared capsular bed after complete resection of the native meniscus.

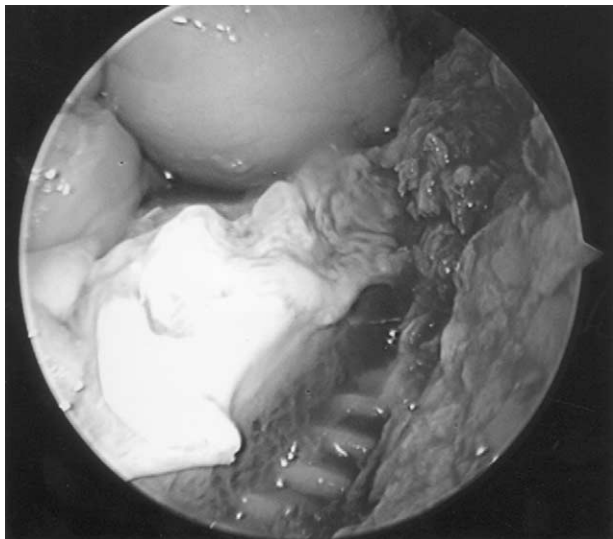


FIGURE 6. Arthroscopic view of the allograft interference screw (bottom) placed adjacent to the meniscal bone bridge (left).

range of motion beyond 90° is permitted within the first 2 postoperative weeks. After 4 weeks, progressive range of motion and activity is allowed, although squatting and pivoting is avoided for 16 weeks. Return to high-level activities is generally between 4 and 6 months.

DISCUSSION

The biomechanical and functional outcome of allograft meniscus transplantation depends on the proper anatomic position and bony fixation of the allograft meniscal horns to normalize contact stresses and surface contact area. Multiple biomechanical studies^{4,6-7} have found that, when considering the articular contact mechanics of various methods of allograft meniscal attachment, bone plug fixation of the meniscal horns produces increased contact area and decreased contact stresses when compared with meniscal horn soft-tissue fixation. Chen et al.⁶ found that meniscal transplantation, with either a tibial bone bridge or with both meniscal horns attached via bone blocks, yielded contact mechanics similar to those seen in an intact knee before meniscectomy, with neither fixation method being superior to the other. In a recent study, Sekeran et al.²³ found that placement of the posterior horn of the medial meniscus transplant in a nonanatomic position increased the contact pressures and shifted the centroid of contact area on the tibial articular surface. These increased contact pressures are

thought to be detrimental to the long-term functional outcome of the allograft meniscus and secondarily to the articular cartilage. Therefore, it appears to be imperative that emphasis be placed on bony fixation of the meniscal horns in precisely the correct anatomic position for optimal biomechanical and functional outcome of the allograft meniscal transplant. The bone bridge technique with allograft cortical bone interference screw allows definitive placement of the meniscal horns at the correct anatomic position while maintaining the necessary bony fixation. The loose bone bridge allows the femoral condyle to capture the meniscus and fine tune the final AP position of the bridge.

The meniscal allograft meniscus bone bridge may be anchored in a variety of ways including suture fixation and titanium, bioabsorbable, or cortical allograft interference screws. Of particular importance is the fixation of the allograft bone bridge within the host tibial slot in order to maintain the proper anatomic position of the meniscal horns. Interference screw fixation has well-established success in ACL reconstruction²² because it allows proper positioning and tensioning of the reconstructed ligament and reliably maintains the correct anatomic position of the ligament during rehabilitation and healing. In a biomechanical study, Kousa et al.²⁴ found no difference between the ultimate failure loads of titanium and bioabsorbable interference screws used in ACL recon-

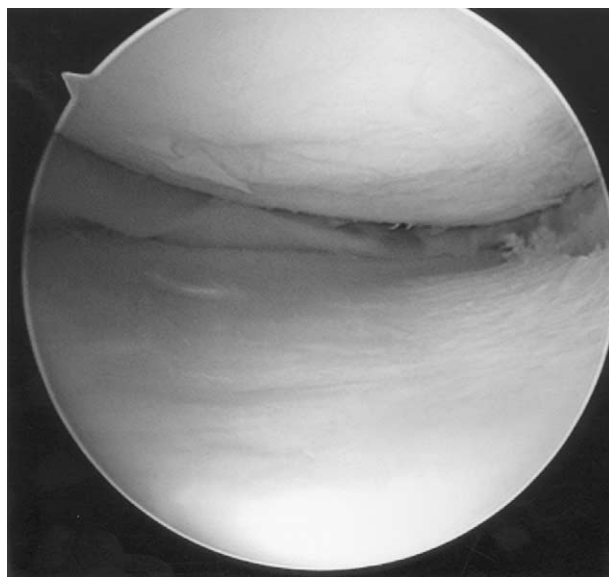


FIGURE 7. Arthroscopic view of the allograft meniscus properly placed and secured to the surrounding capsule.

struction, and they concluded that bioabsorbable interference screw fixation was a reliable alternative to titanium screw fixation. In a study of the fixation strength of titanium and absorbable polyglyconate screws evaluated during the healing process in ACL reconstruction, Walton²⁵ found no difference in the failure strengths between the 2 types of interference screw fixation at up to 12 weeks. Thus, it is evident that a nonmetallic interference screw has the strength necessary to maintain fixation during ligament reconstruction procedures.

Once initial fixation of the allograft bone bridge is established, the subsequent fate of the meniscal transplant relies on the maintenance of the proper meniscal horn position by incorporation of the allograft bone bridge into the host tibial slot and simultaneous healing to the periphery of the capsule. In a recent study of retrieved human allografts, Enneking and Campanacci²⁶ reported that union of the host and allograft cancellous junctions occurred uniformly as early as 4 months postoperatively. Fibrovascular repair tissue of the host marrow penetrated the trabeculae of the allografts to a depth of 2 to 4 mm, united the allograft to the host bone, and remained intact for many years. Therefore, this reparative phenomenon is likely to be present at the interface between the host tibial slot and the allograft meniscal bone bridge in meniscal transplantation, which is likely enhanced by rigid fixation created by the allograft interference screw.

A phenomenon observed in allograft ACL reconstruction is host bone tunnel enlargement. A comparative study showed increased radiographic host bone tunnel enlargement in allograft ACL reconstructions at 1 year compared with autograft.²⁷ The authors postulated various explanations for the increased tunnel diameters observed in the allograft ACL reconstructions including host immune response and rejection to the allogeneic tissue as well as the potential for motion at the allograft-host bone interface, emphasizing the need for secure fixation of the allograft bone. However, this previous study found no correlation between the radiographic bone tunnel enlargement and clinical outcome 1 year postoperatively.²⁷ The cortical allograft interference screws used in our series of patients likely behave in a manner similar to absorbable interference screws rather than those composed of titanium. Furthermore, none of the 34 allograft meniscal transplants reported here had any host tibial slot enlargement or cystic lucencies on latest radiographic evaluation. In a long-term follow-up study by Lajtai et al., biodegradable interference screws used in ACL reconstruction were evaluated using plain radiographs

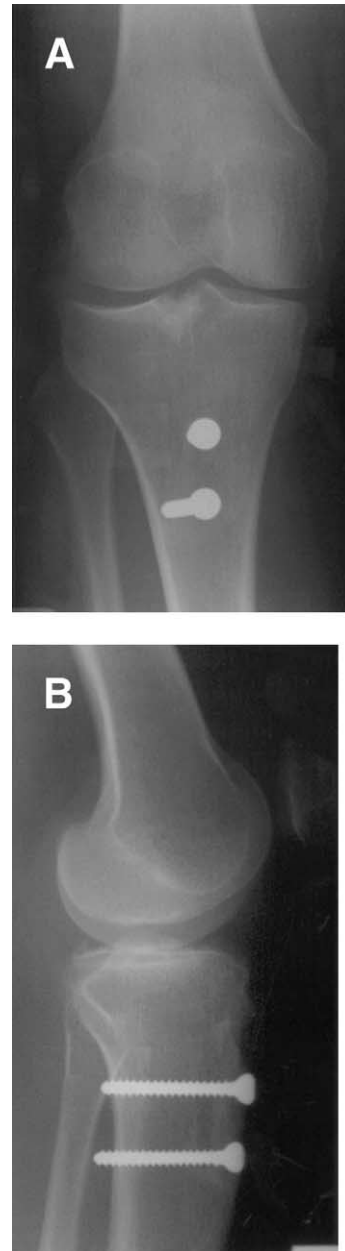


FIGURE 8. Thirteen-month postoperative (A) AP and (B) lateral radiographs of a patient who underwent a lateral meniscal transplant with concurrent autologous chondrocyte implantation and a distal realignment procedure. They show a healed allograft bone bridge without any radiolucency or cystic lesions.

and magnetic resonance imaging at a minimum of 4 years postoperatively. They observed bone remodeling and new bone formation at the site of implantation and no cystic or osteolytic changes were found.²⁸

The lead author (J.F.) has evaluated 34 consecutive allograft meniscal transplants performed using a bone

bridge and allograft cortical bone interference screw fixation. Serial radiographic evaluation of these 33 patients showed that the allograft bone bridge predictably heals within the host tibial slot without displacement or bone tunnel enlargement at an average of 1 year (Fig 8). All bone bridges were seen to be healed on radiographs at the latest follow-up and there was no evidence of bone bridge migration or displacement in either the AP or superoinferior direction. The allograft cortical bone interference screw maintained its original position within the tibial tunnel in all cases and showed varying degrees of incorporation depending on the latest follow-up time point. There were no tibial radiolucencies or cystic lucencies noted on any of the follow-up radiographs. Therefore, the authors believe that using a cortical bone allograft interference screw reliably maintains the anatomic position of meniscal attachments with evidence of radiographic healing, which is critical to the biomechanics and long-term functional outcome of meniscus transplantation.

REFERENCES

1. Fairbank TJ. Knee joint changes after meniscectomy. *J Bone Joint Surg Br* 1948;30:664-670.
2. Jorgensen U, Sonne-Holme S, Lauridsen F, et al. Long-term follow-up of meniscectomy in athletes: A prospective longitudinal study. *J Bone Joint Surg Br* 1987;69:80-83.
3. Hede A, Larsen E, Sandberg H. Partial versus total meniscectomy: A prospective randomized study with long-term follow-up. *J Bone Joint Surg Br* 1992;74:118-121.
4. Alhalki MM, Howell SM, Hull ML. How three methods for fixing a medial meniscal allograft affect tibial contact mechanics. *Am J Sports Med* 1999;27:320-328.
5. Alhalki MM, Hull ML, Howell SM. Contact mechanics of the medial tibial plateau after implantation of a medial meniscal allograft. *Am J Sports Med* 2000;28:370-376.
6. Chen MI, Branch TP, Hutton WC. Is it important to secure the horns during lateral meniscal transplantation? A cadaveric study. *Arthroscopy* 1996;12:174-181.
7. Paletta GA, Manning T, Snell E, et al. The effect of allograft meniscal replacement on intraarticular contact area and pressures in the human knee: A biomechanical study. *Am J Sports Med* 1997;25:692-698.
8. Cameron JC, Saha S. Meniscal allograft transplantation for unicompartmental arthritis of the knee. *Clin Orthop* 1997;337:164-171.
9. Garrett JC, Stevensen RN. Meniscal transplantation in the human knee: A preliminary report. *Arthroscopy* 1991;7:57-62.
10. Milachowski KA, Weismeier K, Wirth CJ. Homologous meniscus transplantation: Experimental and clinical results. *Int Orthop* 1989;13:1-11.
11. Stollsteiner GT, Shelton WR, Dukes A, Bomboy AL. Meniscal allograft transplantation: A 1- to 5-year follow-up of 22 patients. *Arthroscopy* 2000;16:343-347.
12. Van Arkel ER, De Boer HH. Human meniscal transplantation: Preliminary results at 2 to 5-year follow-up. *J Bone Joint Surg Br* 1995;77:589-595.
13. Shelton WR, Dukes AD. Meniscus replacement with bone anchors: A surgical technique. *Arthroscopy* 1994;10:324-327.
14. Wirth CJ, Peters G, Milachowski KA, Weismeier KG, Kohn D. Long-term results of meniscal allograft transplantation. *Am J Sports Med* 2002;30:174-181.
15. Stone KR, Rosenberg T. Surgical technique of meniscal replacement. *Arthroscopy* 1993;9:234-237.
16. Johnson DL. Arthroscopically assisted technique for meniscal reconstruction using fresh frozen allograft. *Oper Tech Orthop* 1995;5:88-94.
17. Kuhn JE, Wojtys EM. Allograft meniscal transplantation. *Clin Sports Med* 1996;15:537-556.
18. Garrett JC. Meniscal transplantation. In: Aichroth PC, Canon WD, Patel DV, eds. *Knee surgery: Current practice*. New York: Raven, 1992;95-103.
19. Wilcox TR, Goble EM. Goble technique of meniscus transplantation. *Am J Knee Surg* 1996;9:1.
20. Brown CH, Hecker AT, Hipp JA, et al. The biomechanics of interference screw fixation of patellar tendon anterior cruciate ligament grafts. *Am J Sports Med* 1993;21:880-886.
21. Kurosaka M, Yoshiya S, Andrich JT. A biomechanical comparison of different surgical techniques of graft fixation in anterior cruciate ligament reconstruction. *Am J Sports Med* 1987;15:225-229.
22. Bach BR, Tradonsky S, Bojchuk J, et al. Arthroscopically assisted anterior cruciate ligament reconstruction using patellar tendon autograft: Five- to nine-year follow-up evaluation. *Am J Sports Med* 1998;26:20-29.
23. Sekeran SV, Hull ML, Howell SM. Nonanatomic location of the posterior horn of a medial meniscus autograft implanted in a cadaveric knee adversely affects the pressure distribution on the tibial plateau. *Am J Sports Med* 2002;30:74-82.
24. Kousa P, Jarvinen TL, Kannus P, Jarvinen M. Initial fixation strength of bioabsorbable and titanium interference screws in anterior cruciate ligament reconstruction: Biomechanical evaluation by single cycle and cyclic loading. *Am J Sports Med* 2001;29:420-425.
25. Walton M. Absorbable and metal interference screws: Comparison of graft security during healing. *Arthroscopy* 1999;15:818-826.
26. Enneking WF, Campanacci DA. Retrieved human allografts. *J Bone Joint Surg Am* 2001;83:971-986.
27. Fahey M, Indelicato PA. Bone tunnel enlargement after anterior cruciate ligament replacement. *Am J Sports Med* 1994;22:410-415.
28. Lajtai G, Schmiedhuber, Unger F, et al. Bone tunnel remodeling at the site of biodegradable interference screws used for anterior cruciate ligament reconstruction: 5-year follow-up. *Arthroscopy* 2001;17:597-602.